CASE SPOTLIGHT | Beyond the Initial Blush: Recognition and Traversal of Collateral Pathways During Genicular Artery Embolization

By Chong Li, MD, RPVI

PATIENT PRESENTATION

A man in his early 80s presented with long-standing bilateral knee osteoarthritis (OA), with the left knee being more symptomatic. He reported progressively worsening knee pain over several years despite conservative management, including physical therapy, oral analgesics, activity modification, and injection therapy. His symptoms had become lifestyle-limiting, significantly reducing his walking tolerance and interfering with daily activities.

Physical examination demonstrated focal tenderness over the medial compartment of the left knee without significant joint instability or effusion. His baseline Western Ontario and McMaster Universities Osteoarthritis Index (WOMAC) score was 72, reflecting substantial pain, stiffness, and functional limitation.

Prior x-rays demonstrated moderate-to-severe bilateral knee OA, consistent with his clinical presentation. He did not want knee replacement and elected to undergo genicular artery embolization (GAE) as a minimally invasive alternative for pain relief.

PROCEDURAL OVERVIEW

The procedure was performed through ultrasound-guided antegrade access of the left superficial femoral artery. A diagnostic angiogram demonstrated multiple prominent genicular branches supplying the symptomatic knee, including the descending and superior medial branch. Abnormal synovial hypervascularity involved both the medial and lateral compartments (more prominent in the former), corresponding to the patient's areas of pain.

A 2.5-F Cantata® microcatheter (Cook Medical) was used to selectively catheterize the target genicular branch vessels. Attention was first directed to the descending genicular artery. Selective angiography demonstrated persistent hypervascularity supplying the symptomatic medial compartment (Figure 1A). Embolization with 0.8 mL of imipenem/cilastatin suspension resulted in near-complete resolution of the abnormal blush (Figure 1B).

Next, selective catheterization and embolization of the superior medial genicular artery was performed using 0.6 mL of an imipenem/cilastatin suspension, again resulting in a marked reduction of the abnormal synovial blush.

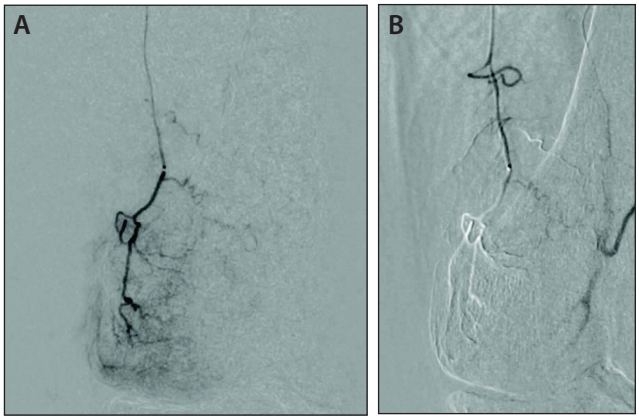

Figure 1. Superselective angiography of the descending genicular artery demonstrating prominent synovial hypervascularity ("blush") corresponding to the patient's symptomatic medial knee compartment prior to embolization (A). Angiography after embolization of the descending genicular artery demonstrating complete resolution of the abnormal hypervascular blush (B).

Repeat angiography then unmasked and opacified a well-developed collateral communicating with the inferior medial genicular artery (IMGA) (Figure 2A). The Cantata microcatheter was advanced through this collateral, and superselective angiography confirmed persistent hypervascularity within the IMGA distribution (Figure 2B). Embolization was then performed using 0.6 mL of imipenem/cilastatin suspension, producing complete resolution of the residual hypervascularity (Figure 2C).

The recurrent genicular artery was subsequently embolized with 1.0 mL of imipenem/cilastatin suspension. Completion angiography demonstrated marked overall reduction of synovial hypervascularity while preserving normal distal arterial perfusion.

Hemostasis was achieved with manual compression following sheath removal, and the patient tolerated the procedure without complications.

OUTCOME AND FOLLOW-UP

The patient experienced progressive improvement in pain and functional capacity during the weeks following

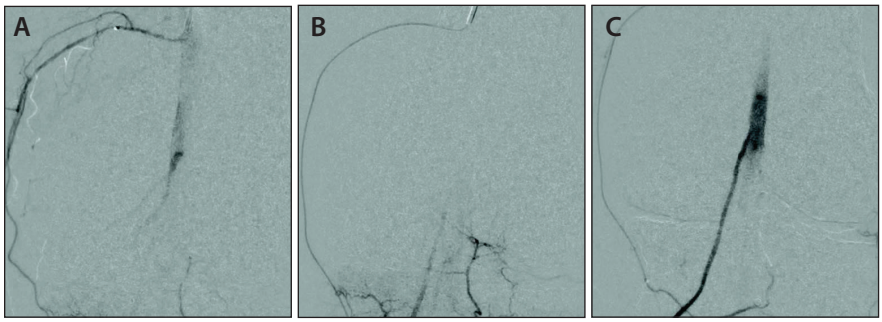

Figure 2. After embolization of the superior medial genicular artery, repeat angiography demonstrated opacification of a robust collateral communicating with the IMGA (A). The Cantata microcatheter was advanced through the collateral into the IMGA; superselective angiography demonstrated persistent synovial hypervascularity within this vascular territory (B). Angiography after embolization of the IMGA through the collateral pathway, demonstrating elimination of the residual hypervascular blush (C).

treatment, and he more easily carried out both daily and leisure activities. At 6-month follow-up, his WOMAC score had improved from 72 preprocedure to 48, representing a clinically meaningful reduction in pain, stiffness, and limitations in daily activities at medium term. He reported improved walking tolerance and expressed a high level of satisfaction with the outcome.

PHYSICIAN DISCUSSION

This case demonstrates the role of GAE as a minimally invasive treatment option for appropriately selected patients with symptomatic knee OA who have failed conservative therapy. Careful angiographic evaluation identified the dominant regions of synovial hypervascularity and allowed selective embolization of the vessels supplying the patient's symptomatic compartments.

An interesting technical aspect of this case was the dynamic angiographic evaluation performed throughout the procedure. After treatment of the dominant superior medial and descending genicular arterial supply, repeat angiography revealed a collateral communicating with the IMGA that became more conspicuous after embolization (Figure 2A). Recognition of this collateral allowed continued interrogation of the symptomatic knee compartment without a separate catheterization, leading to a more complete treatment of the synovial inflammation.

The Cantata microcatheter facilitated this approach by providing stable distal support and predictable navigation through multiple branch orientations, ease of navigation, and trackability. Its shapable distal tip allowed the catheter configuration to be customized for vessels arising at different angles, including superiorly directed branches as well as tortuous takeoffs. Once the collateral was identified, the hydrophilicity and trackability of the catheter allowed advancement through the communicating vessel into the IMGA, where persistent hypervascularity was confirmed (Figure 2B) and successfully treated (Figure 2C).

Although genicular arterial anatomy varies considerably among patients, systematic reassessment after embolization of the dominant target vessels may reveal collateral pathways supplying residual hypervascular synovium. Careful angiographic assessment, combined with a microcatheter capable of navigating complex branch anatomy, can facilitate treatment of these additional vascular territories and may contribute to a more complete embolization while saving procedural and anesthesia time.

At 6 months, the patient's improvement in WOMAC score from 72 to 48 was maintained with a meaningful reduction in pain and functional limitation, supporting the effectiveness of targeted embolization in this appropriately selected patient who underwent a complete embolization. ■

IR-WF1283000-EN-F